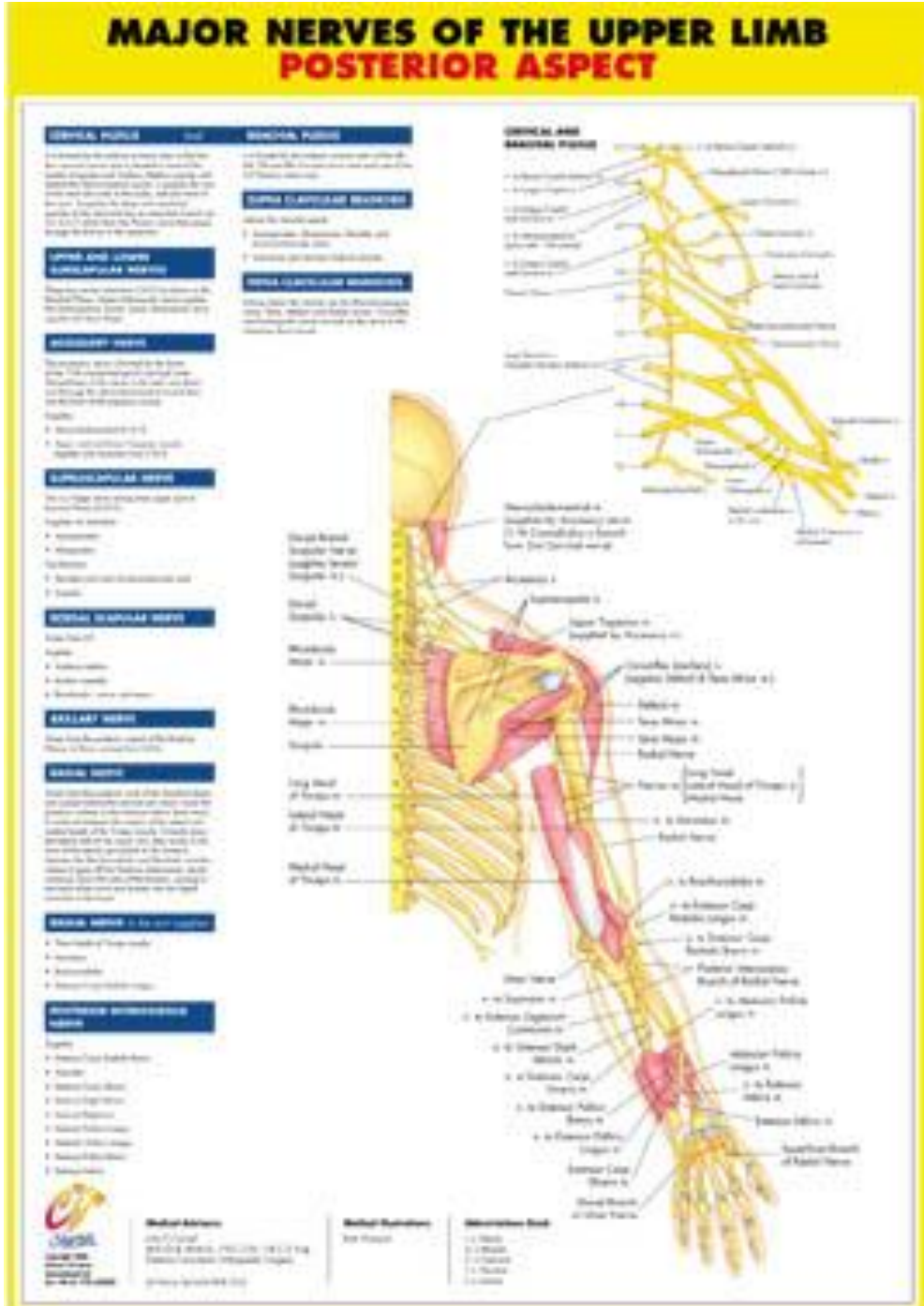


## Human Skull Chart – DG001

<p><b>Description</b></p>	<p>◆ These sturdy, yet flexible anatomical charts are manufactured with 125 micron lamination on both sides. Encompassing a wide range of physical structures and health topics, they combine colorfully detailed diagrams with informative text. Metal eyelets in the top corners allow for easy hanging.</p>
<p><b>Details</b></p>	<ol style="list-style-type: none"> <li>1. Dimension: 20" x 26"</li> <li>2. Material: gloss paper laminated with clear polyester both sides</li> </ol>
<p><b>Image</b></p>	 <p>The chart, titled "MAJOR NERVES OF THE UPPER LIMB POSTERIOR ASPECT", illustrates the complex network of nerves from the cervical spine down to the hand. It includes a detailed diagram of the right arm and hand with numerous labels for nerves and structures. To the left of the diagram are several text boxes providing information on different nerve groups:</p> <ul style="list-style-type: none"> <li><b>CERVICAL NERVE</b>: Lists C1-C8 and their respective innervation areas.</li> <li><b>BRACHIAL PLEXUS</b>: Describes the formation and branches of the plexus.</li> <li><b>UPPER LIMB NERVE</b>: Lists the major nerves of the upper limb.</li> <li><b>SCAPULAR NERVE</b>: Lists the nerves of the scapular region.</li> <li><b>AXILLARY NERVE</b>: Lists the nerves of the axilla.</li> <li><b>BRACHIAL NERVE</b>: Lists the nerves of the brachium.</li> <li><b>ULNAR NERVE</b>: Lists the nerves of the forearm.</li> <li><b>RADIAL NERVE</b>: Lists the nerves of the forearm.</li> <li><b>PERIPHERAL NERVE</b>: Lists the nerves of the hand and fingers.</li> </ul> <p>At the bottom of the chart, there are sections for "Medical Abbreviations", "Medical Symbols", and "Abbreviations Used".</p>